

LENSKYJ, ADAM

ID: 002031473

13-Aug-2019 13:42:04

st michael's hospital

2-Dec-1940

Heart rate 68 bpm

Normal sinus rhythm

Male

PR interval 170 ms

Normal ECG

207 lbs

QRS duration 100 ms

QT/QTc -406/431 ms

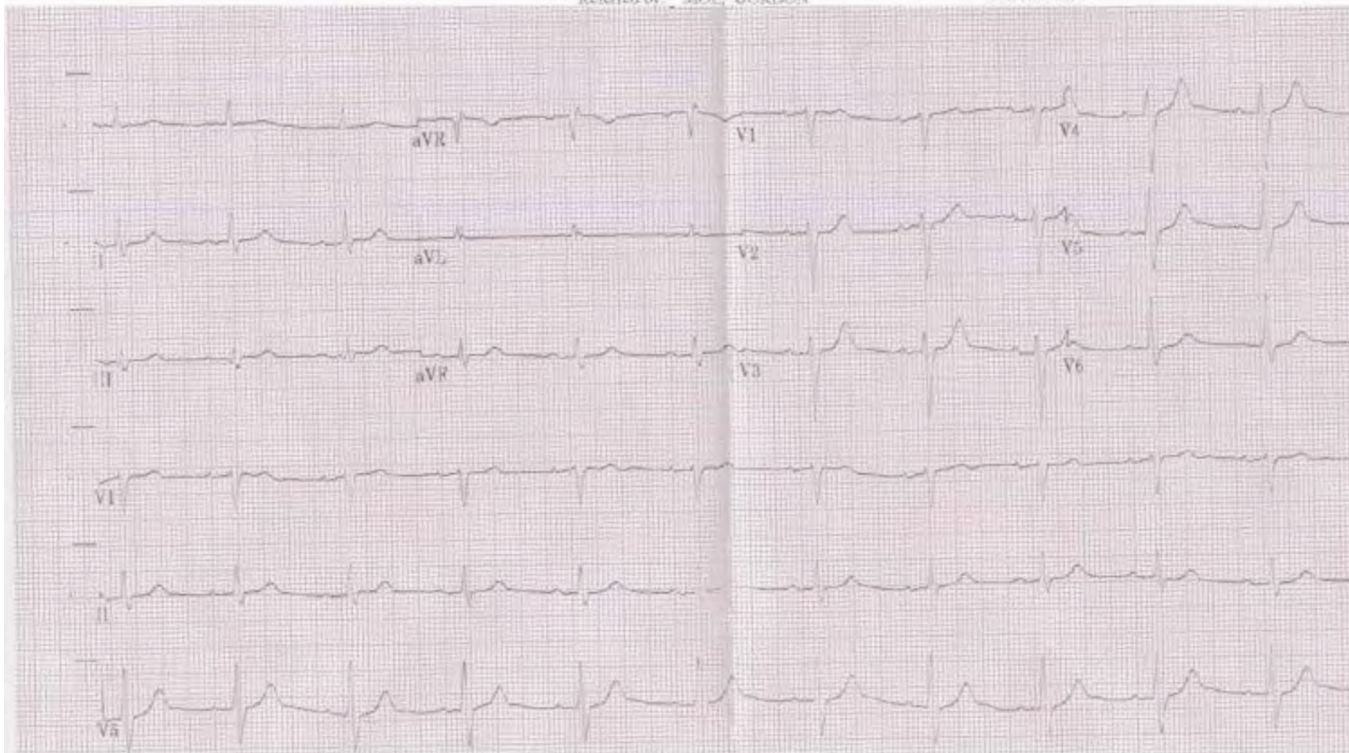
Loe 50

P-R-T axes 39 45 64

Technician: 374

Referred by: MOE, GORDON

Unconfirmed



40 Hz 25.0 mm/s 10.0 mm/mV

4 by 2.5s + 3 rhythm lds

MAC55 010DB

0 12SL™ v241

{Adam L wrote: See original ecg graph in jpg format backed up into photos.google.com at URL:

< https://photos.google.com/share/AF1QipONy6qtARpVzPAdAvCqyUHdaGpte4PutG4SyhG82vrLGHStu3FhVrPKNsVpNA0xg/photo/AF1QipMVS7q-cnUpfiPg_NOjv-bwCZKwft5xwyBoxj?key=WDIRS3JiWEEFjQ2pqNzdnODhDdUdoRy01SEhnY25B >